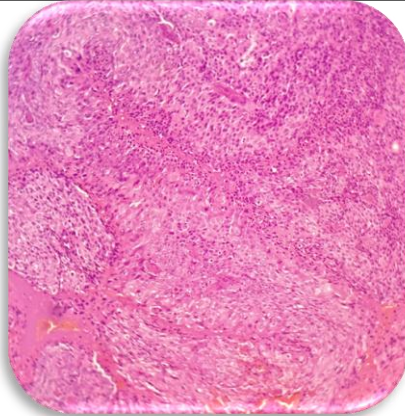


Patient Name	Mrs. SAVITRI	Client Name	Advance Diagnostic	Specimen Received	15/09/2018
Age/Sex	52/F	Client Code	MOLQ1001P	Specimen Type	Tissue
Patient ID	011809150186	Ref. Doctor		Collection Date	15/09/2018
Specimen ID	MOLQ/B-976/18			Report Date	18/09/2018

SURGICAL PATHOLOGY REPORT
ENDOMETRIAL ULCER

DIAGNOSIS

MODERATELY DIFFERENTIATED SQUAMOUS CELL CARCINOMA.



SPECIMEN

Endometrial Ulcer

GROSSING

Received two greyish white tissue pieces, 1x1 cm each.

Microscopy

1. Section examined shows squamous cells with atypical changes like anisonucleosis, altered N:C ratio, mitotic figures invading the stroma in form of islands and cords. Stroma shows inflammatory infiltrate.

Note : All biopsy specimen will be stored for 15 (fifteen) days, block and slides for 5 (five) years only from the time of receipt at the laboratory. No request ,for any of the above ,will be entertained after the due date.

Reference

- i) Rosai and Ackerman's Surgical Pathology.
- ii) Modern Surgical Pathology

Gulshan Yadav, MD
Consultant Pathologist