

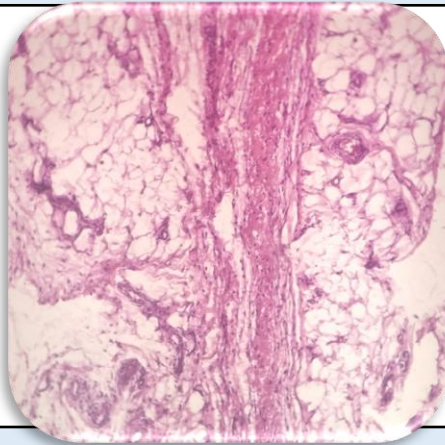
<b>Patient Name</b>	Miss. JANKI	<b>Client Name</b>	Brijanand Path Lab	<b>Specimen Received</b>	15/09/2018
<b>Age/Sex</b>	17/F			<b>Specimen Type</b>	Tissue
<b>Patient ID</b>	011809150059	<b>Client Code</b>	MOLQ1133CM	<b>Collection Date</b>	15/09/2018
<b>Specimen ID</b>	MOLQ/B-975/18	<b>Ref. Doctor</b>		<b>Report Date</b>	17/09/2018

## SURGICAL PATHOLOGY REPORT

### SOFT TISSUE SWELLING RIGHT HAND DORSUM

#### DIAGNOSIS

#### BENIGN MESENCHYMAL LESION



#### SPECIMEN

Soft tissue swelling Right hand dorsum

#### GROSSING

Received 1x2 cm greyish white tissue piece. E/A

#### Microscopy

1. Section examined shows mature adipose cells, fibro collagenous tissue, blood vessels and inflammatory cells. Section shows muscle bundles.
2. No granuloma seen.
3. No malignant cells seen.

**Note :** All biopsy specimen will be stored for 15 (fifteen)days, block and slides for 5(five) years only from the time of receipt at the laboratory. No request ,for any of the above ,will be entertained after the due date.

#### Reference

- i) Rosai and Ackerman's Surgical Pathology.
- ii) Modern Surgical Pathology.
- iii) Shafers, 7<sup>th</sup> edition

**Gulshan Yadav, MD**  
Consultant Pathologist