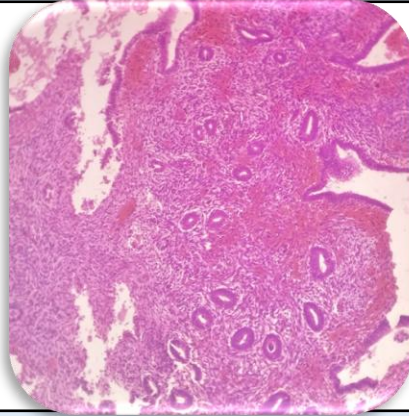


<b>Patient Name</b>	<b>Mrs. VED YADAV</b>	<b>Client Name</b>	Pushpanjali Hospital	<b>Specimen Received</b>	12/09/2018
<b>Age/Sex</b>	49/F		(Rewari)	<b>Specimen Type</b>	Tissue
<b>Patient ID</b>	011809120333	<b>Client Code</b>	MolQ1789CM	<b>Collection Date</b>	12/09/2018
<b>Specimen ID</b>	MOLQ/B-964/18	<b>Ref. Doctor</b>	DR KIRAN	<b>Report Date</b>	17/09/2018

## SURGICAL PATHOLOGY REPORT

### ENDOMETRIUM

#### PROLIFERATIVE PHASE



#### SPECIMEN

Endometrium

#### GROSS

Received multiple greyish white tissue piece.

#### Microscopy

- Section examined shows small endometrial glands with cuboidal lining epithelium. Stroma shows mononuclear inflammatory cells.

**Note :** All biopsy specimen will be stored for 15 (fifteen) days, block and slides for 5 (five) years only from the time of receipt at the laboratory. No request for any of the above, will be entertained after the due date.

#### Reference

- Rosai and Ackerman's Surgical Pathology.
- Modern Surgical Pathology.

**Gulshan Yadav, MD**  
Consultant Pathologist