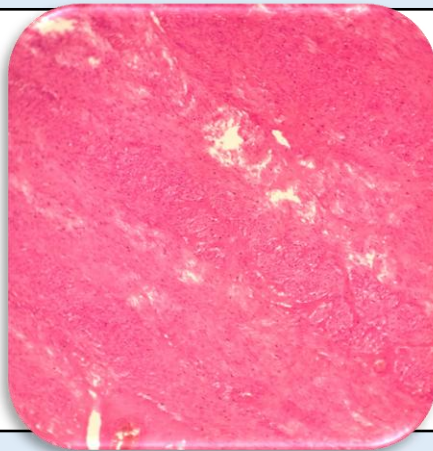


<b>Patient Name</b>	Ms. SWATI	<b>Client Name</b>	Vedic Hospital	<b>Specimen Received</b>	12/09/2018
<b>Age/Sex</b>	22/F	<b>Client Code</b>	MolQ1492CM	<b>Specimen Type</b>	Tissue
<b>Patient ID</b>	011809120284	<b>Ref. Doctor</b>		<b>Collection Date</b>	12/09/2018
<b>Specimen ID</b>	MOLQ/B-958/18			<b>Report Date</b>	17/09/2018

**SURGICAL PATHOLOGY REPORT**  
**DERMOID LEFT ADNEXA**

**DIAGNOSIS**

**BENIGN STROMAL TUMOR (LEIOMYOMA)**



**SPECIMEN**

Dermoid Left Adnexa

**GROSSING**

Received 15 X 14 X 10 cm greyish white cystic tissue piece. Cut section shows greyish white areas. No cystic areas seen. Already capsulated.

**Microscopy**

- Section examined shows interlacing muscle bundles, having small round to oval nucleus, with blood vessels, spindle cells in storiform pattern

**Note :** All biopsy specimen will be stored for 15 (fifteen)days, block and slides for 5(five) years only from the time of receipt at the laboratory. No request ,for any of the above ,will be entertained after the due date.

**Reference**

- Rosai and Ackerman's Surgical Pathology.
- Modern Surgical Pathology.
- Shafers, 7<sup>th</sup> edition

**Gulshan Yadav, MD**  
**Consultant Pathologist**