

Patient Name	Mr. RAMANANEL	Client Name	Pushpanjali Hospital	Specimen Received	11/09/2018
Age/Sex	72/M		(Rewari)	Specimen Type	Tissue
Patient ID	011809110373	Client Code	MolQ1789CM	Collection Date	11/09/2018
Specimen ID	MOLQ/B-954/18	Ref. Doctor	Dr. POOJA	Report Date	17/09/2018

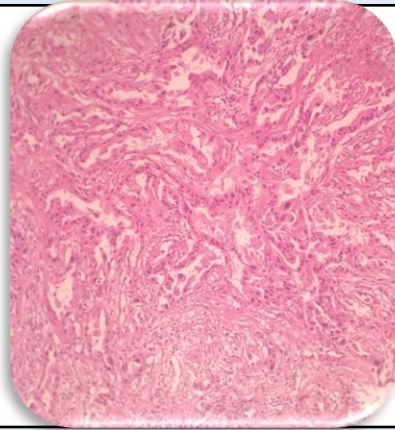
SURGICAL PATHOLOGY REPORT

RUL OF LUNG

DIAGNOSIS

METASTATIC ADENOCARCINOMA (PROSTRATE)

Advised: TTF-1



SPECIMEN

RUL of Lung

GROSSING

Received 1x1cm long greyish white tissue piece.

Microscopy

- Section examined shows cells arranged in glandular pattern having large nucleus with high N:C ratio and atypia and inflammatory cells and normal lung tissue.

Note : All biopsy specimen will be stored for 15 (fifteen)days, block and slides for 5(five) years only from the time of receipt at the laboratory. No request ,for any of the above ,will be entertained after the due date.

Gulshan Yadav, MD
Consultant Pathologist

Reference

- Rosai and Ackerman's Surgical Pathology.
- Modern Surgical Pathology.
- Shafers, 7th edition