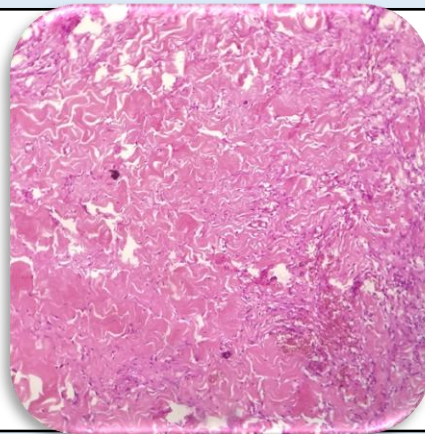


Patient Name	Mrs. SURESH	Client Name	Vedic Hospital	Specimen Received	11/09/2018
Age/Sex	32/F	Client Code	MolQ1492CM	Specimen Type	Tissue
Patient ID	011809110108	Ref. Doctor		Collection Date	11/09/2018
Specimen ID	MOLQ/B-951/18			Report Date	14/09/2018

SURGICAL PATHOLOGY REPORT
TUMOR ON THE UPPER BACK

DIAGNOSIS

FOREIGN BODY TYPE OF GRANULOMA



SPECIMEN

Tumor on the Upper Back

GROSSING

Received 3x4 cm greyish white tissue piece.

Microscopy

- Section examined shows fibrocollagenous tissue, squamous lining epithelium with hyperkeratosis, mature adipose cells with large number of inflammatory cells (polymorphs, lymphocytes, histiocytes, multinucleated giant cells)

Note : All biopsy specimen will be stored for 15 (fifteen)days, block and slides for 5(five) years only from the time of receipt at the laboratory. No request ,for any of the above ,will be entertained after the due date.

Reference

- Rosai and Ackerman's Surgical Pathology.
- Modern Surgical Pathology.

Gulshan Yadav, MD
Consultant Pathologist