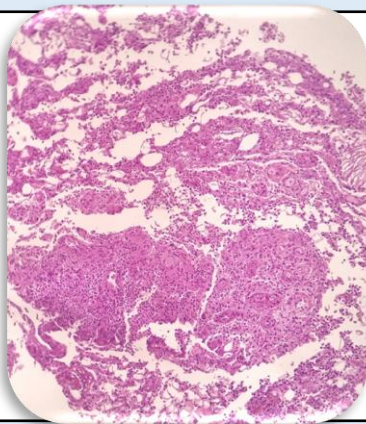


<b>Patient Name</b>	Mrs. Asmeena	<b>Client Name</b>	Arban Hospital	<b>Specimen Received</b>	10/09/2018
<b>Age/Sex</b>	35/F	<b>Client Code</b>	MolQ1789CM	<b>Specimen Type</b>	Tissue
<b>Patient ID</b>	011809100365	<b>Ref. Doctor</b>	DR KIRAN	<b>Collection Date</b>	10/09/2018
<b>Specimen ID</b>	MOLQ/B-949/18			<b>Report Date</b>	13/09/2018

## SURGICAL PATHOLOGY REPORT

### ENDOMETRIUM

**KINDLY, CO-RELATE CLINICALLY AND RADIOLOGICALLY**



#### **SPECIMEN**

Endometrium

#### **GROSS**

Received multiple greyish white tissue piece.

#### **Microscopy**

1. Section examined shows scanty endometrial tissue with stromal cells and inflammatory cells (polymorphs, lymphocytes).
2. No endometrial glands seen in the sample received.

**Note :** All biopsy specimen will be stored for 15 (fifteen) days, block and slides for 5 (five) years only from the time of receipt at the laboratory. No request for any of the above, will be entertained after the due date.

#### **Reference**

- i) Rosai and Ackerman's Surgical Pathology.
- ii) Modern Surgical Pathology.

A handwritten signature in black ink, appearing to read 'Gulshan', written over a light blue rectangular background.

**Gulshan Yadav, MD**  
**Consultant Pathologist**