

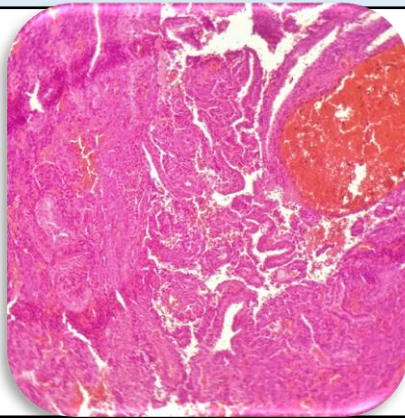
Patient Name	Mrs. NIKKI	Client Name	Chirag Diagnostics	Specimen Received	09/09/2018
Age/Sex	23/F		Gurgaon	Specimen Type	Tissue
Patient ID	011809090106	Client Code	MolQ1214CM	Collection Date	09/09/2018
Specimen ID	MOLQ/B-940/18	Ref. Doctor		Report Date	12/09/2018

SURGICAL PATHOLOGY REPORT

ENDOMETRIUM

DIAGNOSIS

DISORDERED PROLIFERATIVE PHASE



SPECIMEN

Endometrium

GROSS

Received multiple greyish white tissue piece.

Microscopy

- Section examined shows small and tortuous endometrial glands with columnar lining epithelium with round to oval nucleus. Stroma shows mononuclear inflammatory cells.

Note : All biopsy specimen will be stored for 15 (fifteen) days, block and slides for 5 (five) years only from the time of receipt at the laboratory. No request for any of the above, will be entertained after the due date.

Reference

- Rosai and Ackerman's Surgical Pathology.
- Modern Surgical Pathology.

Gulshan Yadav, MD
Consultant Pathologist