

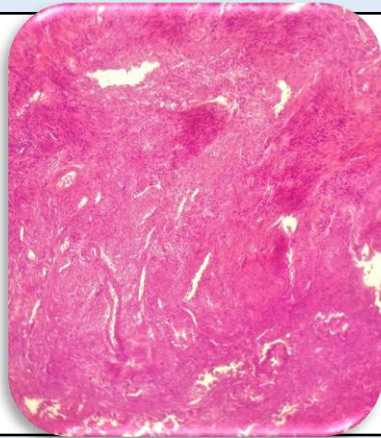
Patient Name	Mrs. Kulsooma	Client Name	A-One Collection Centre, Jammu & Kashmir	Specimen Received	05/09/2018
Age/Sex	34/M	Client Code	MolQ1767P	Specimen Type	Tissue
Patient ID	041809050002	Ref. Doctor		Collection Date	05/09/2018
Specimen ID	MOLQ/B-912-18			Report Date	08/09/2018

SURGICAL PATHOLOGY REPORT

Inflammatory Cyst

DIAGNOSIS

BENIGN MESENCHYMAL LESION



SPECIMEN
Inflammatory Cyst

GROSSING
Received 4x3 cm greyish white tissue piece.

Microscopy

1. Section examined shows squamous epithelial lining with fibro collagenous tissue, glands, mature adipose cells.
2. No granuloma seen.
3. No malignant cells seen.

Note : All biopsy specimen will be stored for 15 (fifteen)days, block and slides for 5(five) years only from the time of receipt at the laboratory. No request ,for any of the above ,will be entertained after the due date.

Reference

- i) Rosai and Ackerman's Surgical Pathology.
- ii) Modern Surgical Pathology.

Gulshan Yadav, MD
Consultant Pathologist