

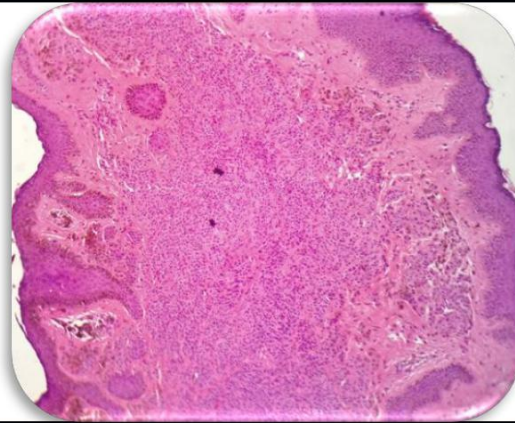
Patient Name	Mrs. VANDANA	Client Name	RLC Path Lab, Samaspur	Specimen Received	05/09/2018
Age/Sex	43/F	Client Code	MolQ1514P	Specimen Type	Tissue
Patient ID	011809050037	Ref. Doctor	DR SAURABH DESWAL	Collection Date	05/09/2018
Specimen ID	MOLQ/B-911-18			Report Date	06/09/2018

SURGICAL PATHOLOGY REPORT

CYST LEFT UPPER EYELID

DIAGNOSIS

IMPRESSION
NEVI (ACTIVE / INTRADERMAL)



SPECIMEN

Cyst left upper eyelid

GROSSING

Received tiny greyish white tissue piece.

Microscopy

1. Section examined shows squamous lining epithelium with round to oval nucleus.
2. Deeper tissue shows epithelial / ovoid cells arranged in sheets and in groups with round to oval nucleus with few spindle cells and melanin pigmentation surrounded by fibrocollagenous tissue.

Note : All biopsy specimen will be stored for 15 (fifteen)days, block and slides for 5(five) years only from the time of receipt at the laboratory. No request ,for any of the above ,will be entertained after the due date.

Reference

- i) Rosai and Ackerman's Surgical Pathology.
- ii) Modern Surgical Pathology.

Gulshan Yadav, MD
Consultant Pathologist