

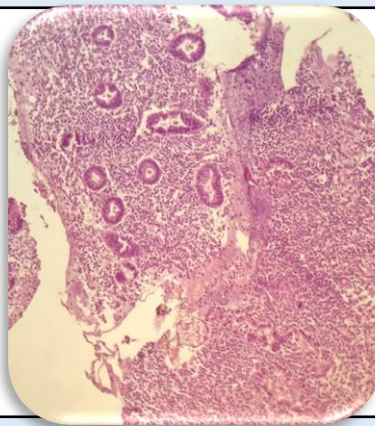
Patient Name	Mrs. UGAMTA	Client Name	Cygnus SuperSpeciality	Specimen Received	29/08/2018
Age/Sex	33/F		Hospital, Rewari	Specimen Type	Tissue
Patient ID	011808290325	Client Code	MolQ1687CM	Collection Date	29/08/2018
Specimen ID	MOLQ/B-893/18	Ref. Doctor		Report Date	31/08/2018

SURGICAL PATHOLOGY REPORT

ENDOMETRIUM

DIAGNOSIS

PROLIFERATIVE PHASE



SPECIMEN

Endometrium.

GROSS

Received tiny greyish white tissue piece. E/A

Microscopy

1. Section examined shows small endometrial glands with columnar lining epithelium, small round nucleus.
2. Stroma shows mononuclear inflammatory cells.

Note : All biopsy specimen will be stored for 15 (fifteen) days, block and slides for 5 (five) years only from the time of receipt at the laboratory. No request for any of the above, will be entertained after the due date.

Reference

- i) Rosai and Ackerman's Surgical Pathology.
- ii) Modern Surgical Pathology.

Gulshan Yadav, MD
Consultant Pathologist