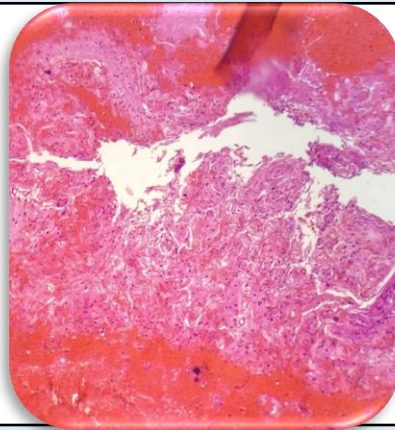


<b>Patient Name</b>	Mrs. MURBI	<b>Client Name</b>	Global Diagnostic Center,	<b>Specimen Received</b>	29/08/2018
<b>Age/Sex</b>	60/F		Tauru	<b>Specimen Type</b>	Tissue
<b>Patient ID</b>	011808290243	<b>Client Code</b>	MolQ1703P	<b>Collection Date</b>	29/08/2018
<b>Specimen ID</b>	MOLQ/B-891-18	<b>Ref. Doctor</b>		<b>Report Date</b>	31/08/2018

**SURGICAL PATHOLOGY REPORT**  
**IRREGULAR GROWTH ON RIGHT VAGINAL WALL**

**DIAGNOSIS**

**ATYPICAL SQUAMOUS EPITHELIAL LESION**



**SPECIMEN**

Irregular Growth on Right Vaginal Wall

**GROSSING**

Received multiple greyish white tissue piece. E/A

**Microscopy**

1. Section examined shows squamous epithelial cells having round to oval nucleus with large number of RBCs and inflammatory cells.
2. Few cells shows anisonucleosis.

**Note :** All biopsy specimen will be stored for 15 (fifteen) days, block and slides for 5 (five) years only from the time of receipt at the laboratory. No request ,for any of the above ,will be entertained after the due date.

**Reference**

- i) Rosai and Ackerman's Surgical Pathology.
- ii) Modern Surgical Pathology.

**Gulshan Yadav, MD**  
**Consultant Pathologist**