

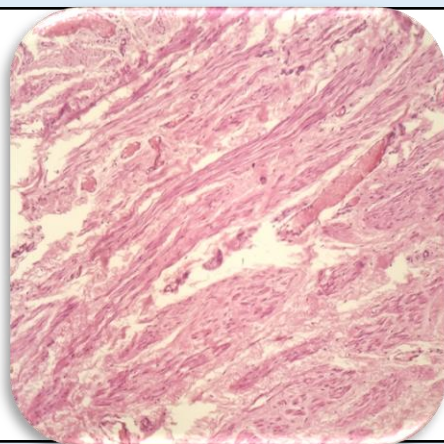
<b>Patient Name</b>	Mrs. REKHA	<b>Client Name</b>	Lalita Memorial Hospital	<b>Specimen Received</b>	28/08/2018
<b>Age/Sex</b>	25/F		Pvt. Ltd. (Rewari)	<b>Specimen Type</b>	Tissue
<b>Patient ID</b>	011808280221	<b>Client Code</b>	MolQ1652P	<b>Collection Date</b>	28/08/2018
<b>Specimen ID</b>	MOLQ/B-886/18	<b>Ref. Doctor</b>		<b>Report Date</b>	31/08/2018

## SURGICAL PATHOLOGY REPORT

### UTERUS WITH CERVIX

#### DIAGNOSIS

**CHRONIC CERVICITIS**



#### SPECIMEN

Uterus with Cervix

#### GROSS

Received 8 x 4.9 cm uterus with cervix with uniloculated cyst. Ovary size: 3x3.5 cm, Ovary cyst size: 2.3 x 2.0 cms containing straw colored fluid.

#### Microscopy


Section examined shows

1. Endometrium with proliferative phase
2. Myometrium with muscle bundles
3. Cervix with mononuclear inflammatory cells.
4. Ovary with simple cyst and tube unremarkable.

**Note :** All biopsy specimen will be stored for 15 (fifteen)days, block and slides for 5(five) years only from the time of receipt at the laboratory. No request ,for any of the above ,will be entertained after the due date.

#### Reference

- i) Rosai and Ackerman's Surgical Pathology.
- ii) Modern Surgical Pathology.

  
**Gulshan Yadav, MD**  
**Consultant Pathologist**