

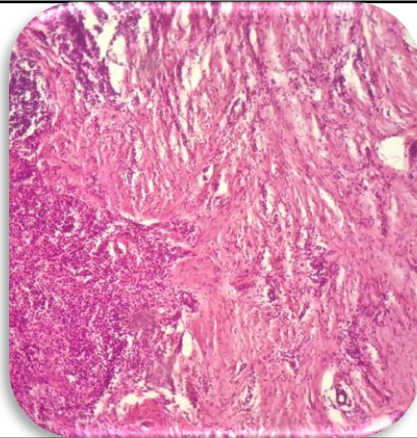
| | | | | | |
|---------------------|---------------|--------------------|------------------|--------------------------|------------|
| Patient Name | Mrs. SUNEETA | Client Name | Civil Hospital-P | Specimen Received | 25/08/2018 |
| Age/Sex | 37/F | Client Code | MolQ1681P | Specimen Type | Tissue |
| Patient ID | 011808250227 | Ref. Doctor | | Collection Date | 25/08/2018 |
| Specimen ID | MOLQ/B-882-18 | | | Report Date | 30/08/2018 |

SURGICAL PATHOLOGY REPORT

RIGHT BREAST

DIAGNOSIS

BENIGN BREAST LESION WITH CHRONIC INFLAMMATION.



SPECIMEN

Right Breast

GROSS

Received two greyish white tissue piece. Size 1x1 cms each.

Microscopy

- Section examined shows squamous epithelial lining with ducts lined by cuboidal lining epithelium surrounded by fibro collagenous tissue and large number of inflammatory cells (Lymphocytes, Plasmacytoid cells).
- No granuloma seen.

Note : All biopsy specimen will be stored for 15 (fifteen)days, block and slides for 5(five) years only from the time of receipt at the laboratory. No request ,for any of the above ,will be entertained after the due date.

Reference

- Rosai and Ackerman's Surgical Pathology.
- Modern Surgical Pathology.

Gulshan Yadav, MD
Consultant Pathologist