

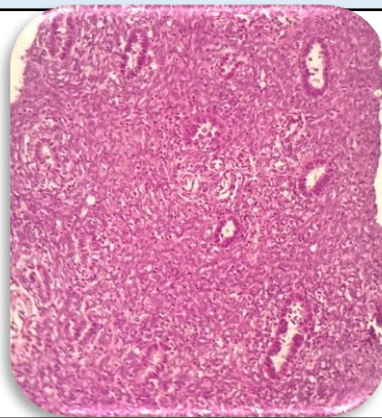
<b>Patient Name</b>	<b>Mrs. MUKESH KUMARI</b>	<b>Client Name</b>	Women Pride Healthcare,	<b>Specimen Received</b>	25/08/2018
<b>Age/Sex</b>	26/F		Rewari	<b>Specimen Type</b>	Tissue
<b>Patient ID</b>	011808250248	<b>Client Code</b>	MolQ1709CM	<b>Collection Date</b>	25/08/2018
<b>Specimen ID</b>	MOLQ/B-883/18	<b>Ref. Doctor</b>	MolQ1709CM	<b>Report Date</b>	28/08/2018

## SURGICAL PATHOLOGY REPORT

### ENDOMETRIUM

#### DIAGNOSIS

#### PROLIFERATIVE PHASE



#### SPECIMEN

Endometrium.

#### GROSS

Received multiple greyish white tissue piece.

#### Microscopy

1. Section examined shows small endometrial glands lined by cuboidal epithelium with mononuclear inflammatory cells.
2. No granuloma seen.
3. No malignant cells seen.

**Note :** All biopsy specimen will be stored for 15 (fifteen) days, block and slides for 5 (five) years only from the time of receipt at the laboratory. No request for any of the above, will be entertained after the due date.

#### Reference

- i) Rosai and Ackerman's Surgical Pathology.
- ii) Modern Surgical Pathology.

A handwritten signature in black ink, appearing to read 'Gulshan', written over a light blue rectangular background.

**Gulshan Yadav, MD**  
Consultant Pathologist