

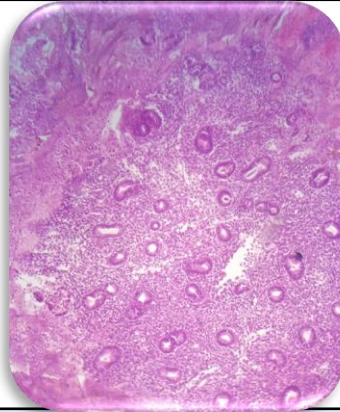
Patient Name	Mrs. KAJAL GOYAL	Client Name	Women Pride Healthcare,	Specimen Received	24/08/2018
Age/Sex	26/F		Rewari	Specimen Type	Tissue
Patient ID	011808240288	Client Code	MolQ1709CM	Collection Date	24/08/2018
Specimen ID	MOLQ/B-876/18	Ref. Doctor		Report Date	28/08/2018

SURGICAL PATHOLOGY REPORT

ENDOMETRIUM

DIAGNOSIS

PROLIFERATIVE PHASE



SPECIMEN

Endometrium.

GROSS

Received multiple greyish white tissue piece.

Microscopy

1. Section Examined Shows Small Endometrial Glands Having Cuboidal Lining Epithelium With Round Nucleus.
2. Stroma Shows Mononuclear Inflammatory Cells.

Note : All biopsy specimen will be stored for 15 (fifteen) days, block and slides for 5 (five) years only from the time of receipt at the laboratory. No request for any of the above, will be entertained after the due date.

Reference

- i) Rosai and Ackerman's Surgical Pathology.
- ii) Modern Surgical Pathology.

Gulshan Yadav, MD
Consultant Pathologist