

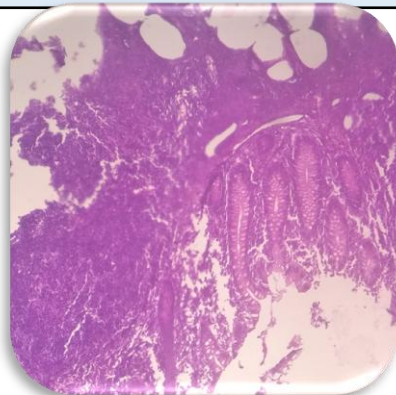
<b>Patient Name</b>	<b>Mr. SAMARPAL</b>	<b>Client Name</b>	Brijanand Path Lab,	<b>Specimen Received</b>	20/08/2018
<b>Age/Sex</b>	33/M	<b>Client Code</b>	MOLQ1133CM	<b>Specimen Type</b>	Tissue
<b>Patient ID</b>	011808200305	<b>Ref. Doctor</b>		<b>Collection Date</b>	20/08/2018
<b>Specimen ID</b>	MOLQ/B-863/18			<b>Report Date</b>	23/08/2018

## SURGICAL PATHOLOGY REPORT

### APPENDIX.

#### DIAGNOSIS

**ACUTE APPENDICITIS.**



#### SPECIMEN

Appendix.

#### GROSS

Received autolyzed 6 x 0.5 cms appendix with mesoappendix.

#### Microscopy

1. Section examined shows autolytic changes in the tissue with lymphoid follicles with ulcerative mucosa.
2. Deeper tissue shows inflammatory cells.

**Note :** All biopsy specimen will be stored for 15 (fifteen) days, block and slides for 5 (five) years only from the time of receipt at the laboratory. No request, for any of the above, will be entertained after the due date.

#### Reference

- i) Rosai and Ackerman's Surgical Pathology.
- ii) Modern Surgical Pathology.

**Gulshan Yadav, MD**  
Consultant Pathologist