

Patient Name	Mrs. AMITA	Client Name	Vaanya Pvt. Ltd.	Specimen Received	08/08/2018
Age/Sex	31/F			Specimen Type	Block No-1141/18
Patient ID	011808080303	Client Code	MolQ1322P	Collection Date	08/08/2018
Specimen ID	MOLQ/IHC-30/08/2018	Ref. Doctor	DR.HARMEET SINGH	Report Date	20/08/2018

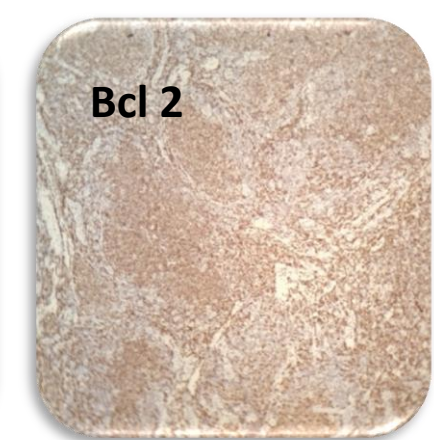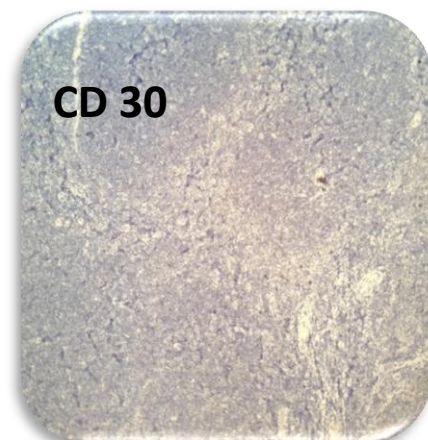
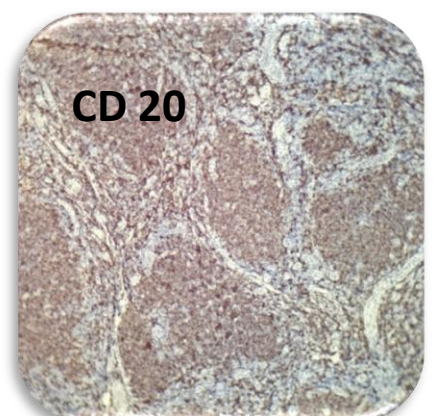
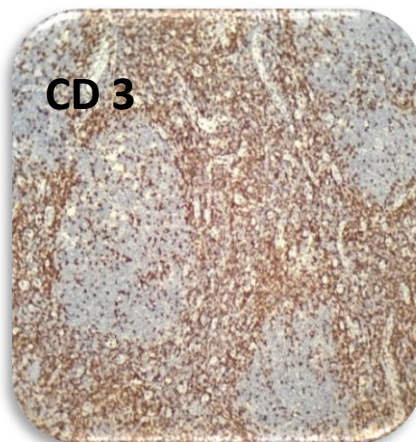
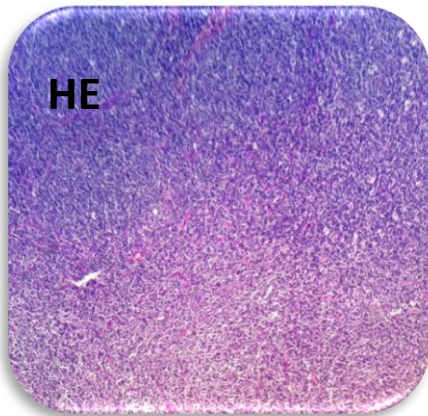
SURGICAL PATHOLOGY REPORT

DIAGNOSIS

FOLLICULAR NON-HODGKIN'S LYMPHOMA

Note: Final Diagnosis is Based On Immunohistochemistry Done.

(CD 3: POSITIVE, CD 20: POSITIVE, CD 30: NEGATIVE, Ki-67: POSITIVE, Bcl 2: POSITIVE)



Microscopic Findings:

Cluster of Differentiation 3 (CD 3)

% Cells immunoreactive –80%
Intensity- 3+
Internal control-Positive
Interpretation-Positive

Cluster of Differentiation 20 (CD 20)

% Cells immunoreactive –90%
Intensity- 4+
Internal control-Positive
Interpretation-Positive

Cluster of Differentiation 3 (CD 30)

% Cells immunoreactive –00%
Intensity- Not Applicable
Internal control-Positive
Interpretation-Negative

Ki 67

% Cells immunoreactive –10%
Intensity- 2+
Internal control-Positive
Interpretation-Positive

Basal Cell Lymphoma 2 (Bcl 2)


% Cells immunoreactive –80%
Intensity- 4+
Internal control-Positive
Interpretation-Positive

SPECIMEN

Left Axillary Lymph Node
(BLOCK NO. 1141/18)

Reference

- i) Rosai and Ackerman's Surgical Pathology.
- ii) Modern Surgical Pathology.



Gulshan Yadav, MD
Consultant Pathologist