

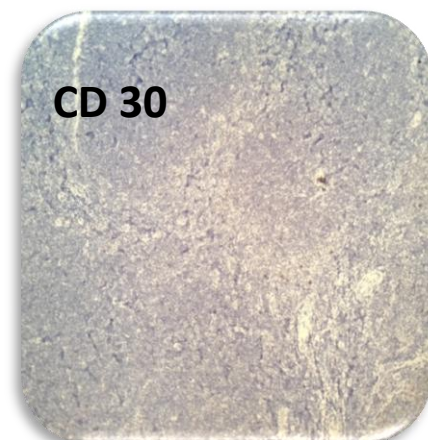
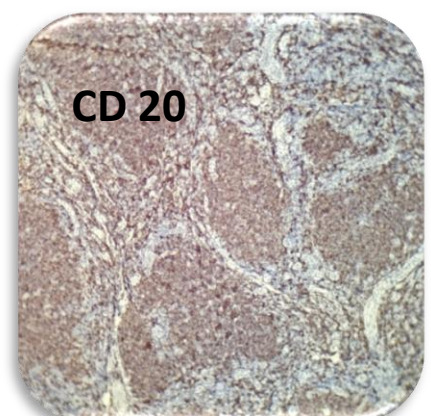
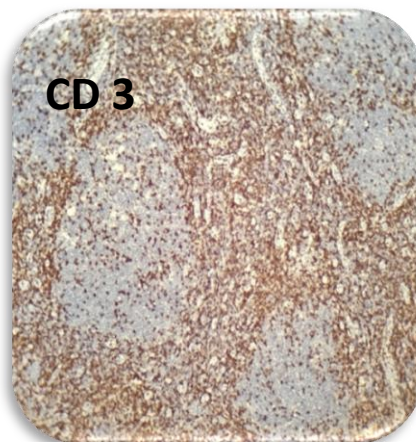
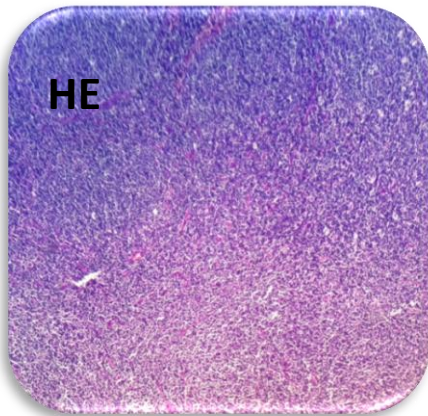
<b>Patient Name</b>	Mrs. AMITA	<b>Client Name</b>	Vaanya Pvt. Ltd.	<b>Specimen Received</b>	08/08/2018
<b>Age/Sex</b>	31/F			<b>Specimen Type</b>	Tissue
<b>Patient ID</b>	011808080303	<b>Client Code</b>	MolQ1322P	<b>Collection Date</b>	08/08/2018
<b>Specimen ID</b>	MOLQ/IHC-30/08/2018	<b>Ref. Doctor</b>	DR.HARMEET SINGH	<b>Report Date</b>	20/08/2018

## **SURGICAL PATHOLOGY REPORT**

### **NON-HODGKIN'S LYMPHOMA**

#### **DIAGNOSIS**

**CD 3: POSITIVE**  
**CD 20: POSITIVE**  
**CD 30: NEGATIVE**  
**Ki-67: POSITIVE**  
**Bcl 2: POSITIVE**



**Microscopic Findings:**

**Cluster of Differentiation 3 (CD 3)**

% Cells immunoreactive –80%

Intensity- 3+

Internal control-Positive

Interpretation-Positive

**Cluster of Differentiation 20 (CD 20)**

% Cells immunoreactive –90%

Intensity- 4+

Internal control-Positive

Interpretation-Positive

**Cluster of Differentiation 3 (CD 30)**

% Cells immunoreactive –00%

Intensity- Not Applicable

Internal control-Positive

Interpretation-Negative

**Ki 67**

% Cells immunoreactive –10%

Intensity- 2+

Internal control-Positive

Interpretation-Positive

**Basal Cell Lymphoma 2 (Bcl 2)**

% Cells immunoreactive –80%

Intensity- 4+

Internal control-Positive

Interpretation-Positive

**SPECIMEN**

Left Axillary Lymph Node

**Reference**

- i) Rosai and Ackerman's Surgical Pathology.
- ii) Modern Surgical Pathology.



**Gulshan Yadav, MD**  
Consultant Pathologist