

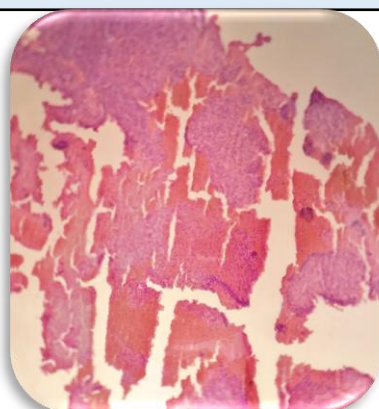
Patient Name	Mrs. BABLI	Client Name	Cygnus SuperSpeciality	Specimen Received	08/08/2018
Age/Sex	34/F		Hospital, Rewari	Specimen Type	Tissue
Patient ID	011808080341	Client Code	MolQ1687CM	Collection Date	08/08/2018
Specimen ID	MOLQ/B-828/18	Ref. Doctor		Report Date	13/08/2018

SURGICAL PATHOLOGY REPORT

ENDOMETRIUM

DIAGNOSIS

ENDOMETRIAL POLYP



SPECIMEN

Endometrium.

GROSS

Received 1x2 cm greyish white tissue piece. E/A

Microscopy

1. Section examined shows endometrial lining epithelium with cuboidal cells and small round nucleus.
2. Stroma shows mononuclear inflammatory cells.
3. No granuloma seen.
4. No malignant cells seen in sample received.

Note : All biopsy specimen will be stored for 15 (fifteen)days, block and slides for 5(five) years only from the time of receipt at the laboratory. No request ,for any of the above ,will be entertained after the due date.

Reference

- i) Rosai and Ackerman's Surgical Pathology.
- ii) Modern Surgical Pathology.

Gulshan Yadav, MD
Consultant Pathologist