

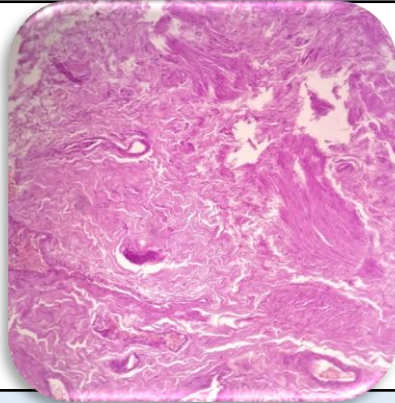
| | | | | | |
|---------------------|---------------|--------------------|----------------|--------------------------|------------|
| Patient Name | Mrs. ANGURI | Client Name | Arban Hospital | Specimen Received | 07/08/2018 |
| Age/Sex | 55/F | | Nuh | Specimen Type | Tissue |
| Patient ID | 011808070336 | Client Code | MolQ1684P | Collection Date | 07/08/2018 |
| Specimen ID | MOLQ/B-820-18 | Ref. Doctor | | Report Date | 13/08/2018 |

SURGICAL PATHOLOGY REPORT

GALL BLADDER.

DIAGNOSIS

CHOLECYSTITIS AND CHOLELITHIASIS.



SPECIMEN

Gall Bladder.

GROSS

Received 5.0 x 2.8 cm long gall bladder.

Microscopy

1. Section examined shows ulcerative mucosa and rokitansky aschoff sinus with fibrocollagenous tissue.

Note : All biopsy specimen will be stored for 15 (fifteen)days, block and slides for 5(five) years only from the time of receipt at the laboratory. No request ,for any of the above ,will be entertained after the due date.

Reference

- i) Rosai and Ackerman's Surgical Pathology.
- ii) Modern Surgical Pathology.

A handwritten signature in black ink, appearing to read 'Gulshan', written over a light blue rectangular background.

**Gulshan Yadav, MD
Consultant Pathologist**