

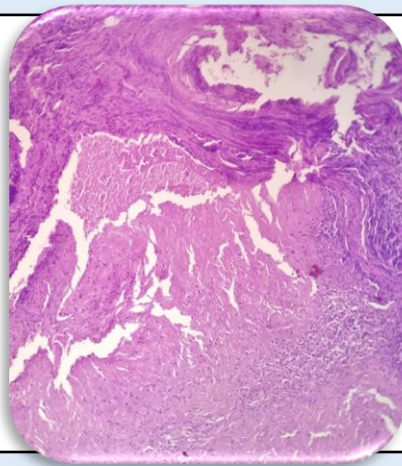
<b>Patient Name</b>	Master. ASHU	<b>Client Name</b>	Civil Hospital P, Gurgaon.	<b>Specimen Received</b>	07/07/2018
<b>Age/Sex</b>	12/M	<b>Client Code</b>	MolQ1681P	<b>Specimen Type</b>	Tissue
<b>Patient ID</b>	011808070256	<b>Ref. Doctor</b>	DR PRADEEP YADAV	<b>Collection Date</b>	07/07/2018
<b>Specimen ID</b>	MOLQ/B-819-18			<b>Report Date</b>	11/07/2018

## SURGICAL PATHOLOGY REPORT

### LYMPH NODE? LIPOMA?

#### DIAGNOSIS

**GRANULOMATOUS LYMPHADENITIS (TUBERCULAR PATHOLOGY STRONGLY SUSPICIOUS)**



#### SPECIMEN

Lymph Node? Lipoma?

#### GROSS

Received 1x1cm greyish white tissue piece.

#### Microscopy

- Section examined shows lymphocytes, centrocytes and histiocytes / epitheloid cells with caseous necrosis.

**Note :** All biopsy specimen will be stored for 15 (fifteen)days, block and slides for 5(five) years only from the time of receipt at the laboratory. No request ,for any of the above ,will be entertained after the due date.

#### Reference

- Rosai and Ackerman's Surgical Pathology.
- Modern Surgical Pathology.

**Gulshan Yadav, MD**  
Consultant Pathologist