

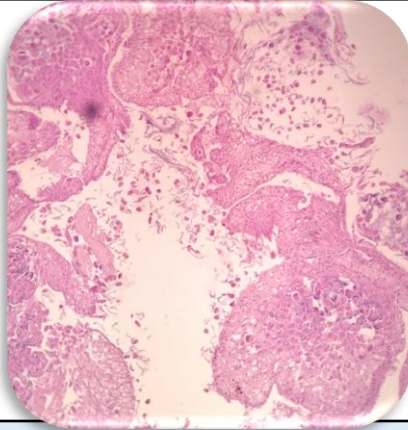
<b>Patient Name</b>	<b>Mrs. NAMRATA</b>	<b>Client Name</b>	Citywide Pathology & Referral Laboratories , Gurgaon	<b>Specimen Received</b>	05/08/2018
<b>Age/Sex</b>	31/F	<b>Client Code</b>	MolQ1754P	<b>Specimen Type</b>	Tissue
<b>Patient ID</b>	011808050102	<b>Ref. Doctor</b>		<b>Collection Date</b>	05/08/2018
<b>Specimen ID</b>	MOLQ/B-812-18			<b>Report Date</b>	08/08/2018

## SURGICAL PATHOLOGY REPORT

### CYST? LEFT EYE LID

#### DIAGNOSIS

**MOLAR PREGNANCY**



#### SPECIMEN

Cyst? Left eye lid

#### GROSSING

Received 05 x 0.5 cm greyish white tissue piece.

#### Microscopy

- Section examined shows squamous lining epithelium with keratin flakes with viral inclusion bodies surrounded by fibro collagenous tissue.

**Note :** All biopsy specimen will be stored for 15 (fifteen)days, block and slides for 5(five) years only from the time of receipt at the laboratory. No request ,for any of the above ,will be entertained after the due date.

#### Reference

- Rosai and Ackerman's Surgical Pathology.
- Modern Surgical Pathology.

**Gulshan Yadav, MD**  
**Consultant Pathologist**