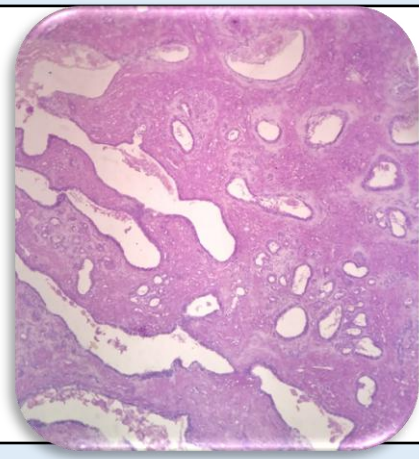


<b>Patient Name</b>	Mrs. RADIKA	<b>Client Name</b>	Patient Care Diagnostics,	<b>Specimen Received</b>	03/08/2018
<b>Age/Sex</b>	35/F		Faridabad	<b>Specimen Type</b>	Tissue
<b>Patient ID</b>	011808030270	<b>Client Code</b>	MolQ1774CM	<b>Collection Date</b>	03/08/2018
<b>Specimen ID</b>	MOLQ/B-803-18	<b>Ref. Doctor</b>		<b>Report Date</b>	07/08/2018

**SURGICAL PATHOLOGY REPORT**  
**FIBROADENOMA ? LEFT BREAST**

**DIAGNOSIS**

**BENIGN BREAST LESION.**



**SPECIMEN**  
 Fibroadenoma ? Left Breast

**GROSS**  
 Received 3x4 cm greyish white tissue piece.

**Microscopy**

- Section examined shows large number of ducts with cuboidal lining epithelium, few ducts are cystically dilated surrounded by fibro collagenous tissue and myoepithelial cells.

**Note :** All biopsy specimen will be stored for 15 (fifteen)days, block and slides for 5(five) years only from the time of receipt at the laboratory. No request ,for any of the above ,will be entertained after the due date.

- Reference**
- Rosai and Ackerman's Surgical Pathology.
  - Modern Surgical Pathology.

**Gulshan Yadav, MD**  
**Consultant Pathologist**