

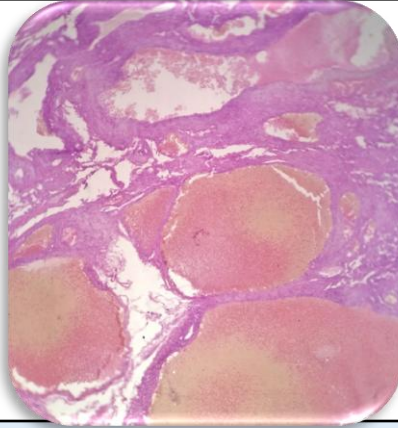
Patient Name	Mr. NIRMALA	Client Name	Civil Hospital-P	Specimen Received	03/08/2018
Age/Sex	40/M		Gurgaon	Specimen Type	Tissue
Patient ID	011808030267	Client Code	MolQ1681P	Collection Date	03/08/2018
Specimen ID	MOLQ/B-802-18	Ref. Doctor		Report Date	07/08/2018

SURGICAL PATHOLOGY REPORT

PILES

DIAGNOSIS

HEMORROIDS



SPECIMEN

Piles

GROSSING

Received 3x2 cm greyish white tissue piece.

Microscopy

- Section examined shows squamous epithelial lining, fibro collagenous tissue with large number of blood vessels.

Note : All biopsy specimen will be stored for 15 (fifteen)days, block and slides for 5(five) years only from the time of receipt at the laboratory. No request ,for any of the above ,will be entertained after the due date.

Reference

- Rosai and Ackerman's Surgical Pathology.
- Modern Surgical Pathology.

Gulshan Yadav, MD
Consultant Pathologist