

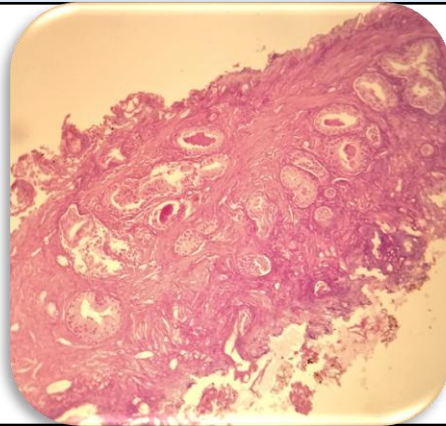
<b>Patient Name</b>	<b>Mr. CHAJJU RAM</b>	<b>Client Name</b>	Samvedna Hospital, Narnaul	<b>Specimen Received</b>	01/08/2018
<b>Age/Sex</b>	85/M	<b>Client Code</b>	MolQ1794CW	<b>Specimen Type</b>	Tissue
<b>Patient ID</b>	011808010339	<b>Ref. Doctor</b>		<b>Collection Date</b>	01/08/2018
<b>Specimen ID</b>	MOLQ/B-788-18			<b>Report Date</b>	06/08/2018

## SURGICAL PATHOLOGY REPORT

### TURP

#### DIAGNOSIS

**CHRONIC INFLAMMATION**



#### SPECIMEN

TURP

#### GROSSING

Received multiple greyish white tissue piece 5x3 cm in aggregate.

#### Microscopy

1. Section examined shows bilayered prostatic glands with columnar lining epithelium and with small round to oval nucleus surrounded by large number of fibrocollagenous tissue and mononuclear inflammatory cell.

**Note :** All biopsy specimen will be stored for 15 (fifteen) days, block and slides for 5 (five) years only from the time of receipt at the laboratory. No request ,for any of the above ,will be entertained after the due date.

#### Reference

- i) Rosai and Ackerman's Surgical Pathology.
- ii) Modern Surgical Pathology.

**Gulshan Yadav, MD**  
**Consultant Pathologist**