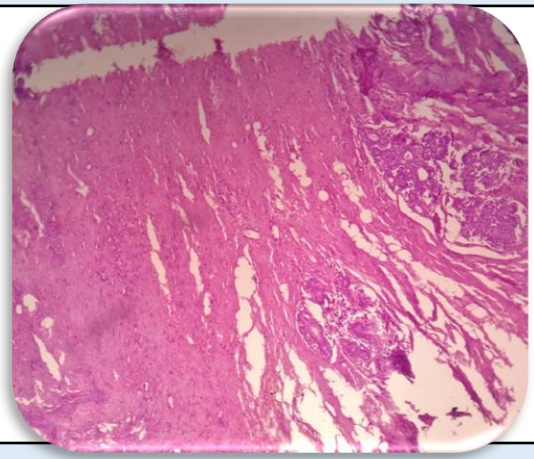


| | | | | | |
|---------------------|---------------|--------------------|---------------------------|--------------------------|------------|
| Patient Name | Ms. JYOTI | Client Name | Patient Care Diagnostics, | Specimen Received | 02/08/2018 |
| Age/Sex | 18/F | | Faridabad | Specimen Type | Tissue |
| Patient ID | 011808010198 | Client Code | MolQ1774CM | Collection Date | 02/08/2018 |
| Specimen ID | MOLQ/B-787-18 | Ref. Doctor | SHRI RAM HOSPITAL | Report Date | 06/08/2018 |

SURGICAL PATHOLOGY REPORT
FIBROADENOMA ? LEFT BREAST

DIAGNOSIS

BENIGN BREAST LESION.



SPECIMEN

Fibroadenoma ? Left Breast

GROSS

Received multiple greyish white tissue piece 4.0x4.0cm.

Microscopy

- Section examined shows large number of ducts with cuboidal to columnar lining epithelial, few duct are cystically dilated surrounding by fibrocollagenous tissue with myoepithelial cells.

Note : All biopsy specimen will be stored for 15 (fifteen)days, block and slides for 5(five) years only from the time of receipt at the laboratory. No request ,for any of the above ,will be entertained after the due date.

Reference

- Rosai and Ackerman's Surgical Pathology.
- Modern Surgical Pathology.

Gulshan Yadav, MD
Consultant Pathologist