

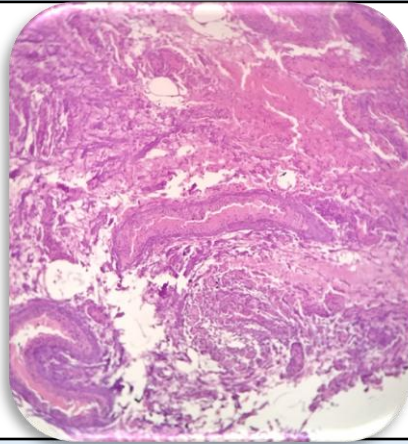
<b>Patient Name</b>	Mrs. SUNITA DEVI	<b>Client Name</b>	Accurate Path (C), Agra	<b>Specimen Received</b>	01/08/2018
<b>Age/Sex</b>	28/F	<b>Client Code</b>	MolQ1671P	<b>Specimen Type</b>	Tissue
<b>Patient ID</b>	011808010010	<b>Ref. Doctor</b>	DR JYOTI GUPTA MD	<b>Collection Date</b>	01/08/2018
<b>Specimen ID</b>	MOLQ/B-784-18			<b>Report Date</b>	04/08/2018

## SURGICAL PATHOLOGY REPORT

### ECTOPIC BIOPSY

#### DIAGNOSIS

**ECTOPIC BIOPSY**



#### SPECIMEN

Ectopic Biopsy

#### GROSS

Received multiple greyish white tissue piece with blood clot with tube.

#### Microscopy

1. Section examined shows autolytic changes in the submucosal glands with squamous epithelial cells having small round nucleus with fibro collagenous tissue, blood vessels and inflammatory cells.
2. No granuloma seen.
3. No malignant cells seen in the sample received.

**Note :** All biopsy specimen will be stored for 15 (fifteen) days, block and slides for 5 (five) years only from the time of receipt at the laboratory. No request, for any of the above, will be entertained after the due date.

#### Reference

- i) Rosai and Ackerman's Surgical Pathology.
- ii) Modern Surgical Pathology.

**Gulshan Yadav, MD**  
**Consultant Pathologist**