

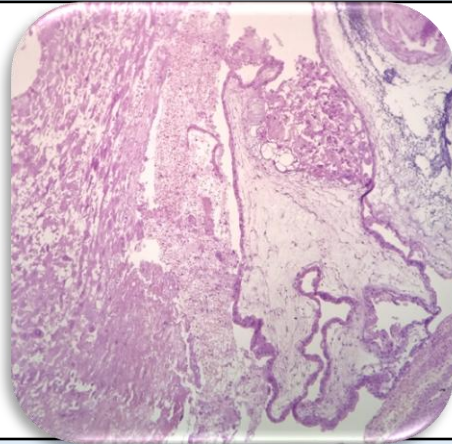
Patient Name	Mrs. KAMINI DEVI	Client Name	Accurate Path (C), Agra	Specimen Received	01/08/2018
Age/Sex	47/M	Client Code	MolQ1671CM	Specimen Type	Tissue
Patient ID	011808010009	Ref. Doctor	DR JYOTI GUPTA MD	Collection Date	01/08/2018
Specimen ID	MOLQ/B-783-18			Report Date	04/08/2018

SURGICAL PATHOLOGY REPORT

VESICULAR MOLE

DIAGNOSIS

VESICULAR MOLE



SPECIMEN
VESICULAR MOLE

GROSS
Received multiple greyish white tissue piece.

Microscopy

1. Section examined shows trophoblastic cells with hydropic changes, decidual cells and blood vessels.

Note : All biopsy specimen will be stored for 15 (fifteen) days, block and slides for 5 (five) years only from the time of receipt at the laboratory. No request, for any of the above, will be entertained after the due date.

Reference

- i) Rosai and Ackerman's Surgical Pathology.
- ii) Modern Surgical Pathology.

Gulshan Yadav, MD
Consultant Pathologist