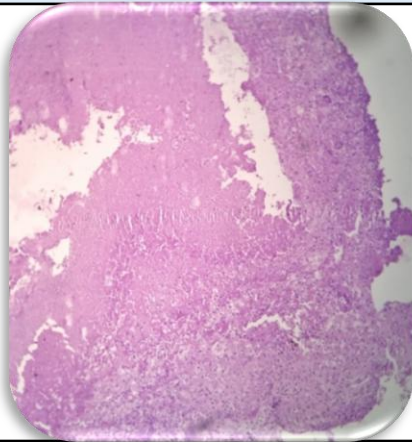


Patient Name	Mr. SATYA PRAKASH	Client Name	Samvedna Hospital, Narnaul	Specimen Received	31/07/2018
Age/Sex	47/M	Client Code	MOLQ1095CM	Specimen Type	Tissue
Patient ID	011807310312	Ref. Docto		Collection Date	31/07/2018
Specimen ID	MOLQ/B-782-18			Report Date	04/08/2018

SURGICAL PATHOLOGY REPORT
WOUND SCRAPING (GLUTEAL SCRAPING)

DIAGNOSIS

CHRONIC NECROTIZING LESION.(Kindly rule out tubercular pathology).



SPECIMEN

Wound Scraping (Gluteal Scraping)

GROSS

Received greyish white tissue piece E/A.

Microscopy

- Section examined shows Squamous epithelial cell lining with small round nucleus section shows necrosis lymphocyte monocyte and histiocytes, few multinucleated cells.

Note : All biopsy specimen will be stored for 15 (fifteen)days, block and slides for 5(five) years only from the time of receipt at the laboratory. No request ,for any of the above ,will be entertained after the due date.

Reference

- Rosai and Ackerman's Surgical Pathology.
- Modern Surgical Pathology.

Gulshan Yadav, MD
Consultant Pathologist