

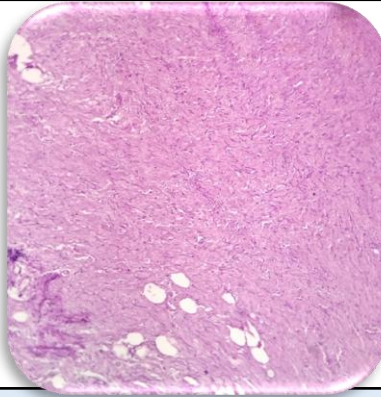
| | | | | | |
|---------------------|---------------|--------------------|--------------------|--------------------------|------------|
| Patient Name | Mr. DHANPATI | Client Name | Advance Diagnostic | Specimen Received | 30/07/2018 |
| Age/Sex | 65/M | | (O) Manesar | Specimen Type | Tissue |
| Patient ID | 011807300275 | Client Code | MOLQ1001P | Collection Date | 30/07/2018 |
| Specimen ID | MOLQ/B-779-18 | Ref. Doctor | | Report Date | 03/07/2018 |

SURGICAL PATHOLOGY REPORT

GALL BLADDER.

DIAGNOSIS

CHOLECYSTITIS AND CHOLELITHIASIS.



SPECIMEN

Gall Bladder.

GROSS

Received 3x4 cm long gall bladder already cut open with tiny stone wall thickening.

Microscopy

1. Section examined shows ulcerative mucosa and Rokitansky-Aschoff sinuses with fibrocollagenous tissue.

Note : All biopsy specimen will be stored for 15 (fifteen) days, block and slides for 5 (five) years only from the time of receipt at the laboratory. No request, for any of the above, will be entertained after the due date.

Reference

- i) Rosai and Ackerman's Surgical Pathology.
- ii) Modern Surgical Pathology.

**Gulshan Yadav, MD
Consultant Pathologist**