

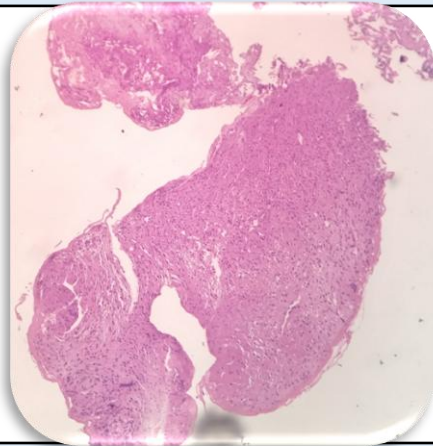
<b>Patient Name</b>	<b>Baby. PAYAL</b>	<b>Client Name</b>	Polaris Hospital, Gurgoan	<b>Specimen Received</b>	27/07/2018
<b>Age/Sex</b>	13/F	<b>Client Code</b>	MOLQ1098CM	<b>Specimen Type</b>	Tissue
<b>Patient ID</b>	011807270138	<b>Ref. Docto</b>		<b>Collection Date</b>	27/07/2018
<b>Specimen ID</b>	MOLQ/B-767-18			<b>Report Date</b>	03/07/2018

## SURGICAL PATHOLOGY REPORT

### T1-T2 SPONDYLITIS

#### DIAGNOSIS

**NECROTIZING GRANULOMATOUS INFLAMMATION.**



#### **SPECIMEN**

T1-T2 Spondylitis

#### **GROSS**

Received multiple greyish white tissue piece.

#### **Microscopy**

1. Section examined shows cartilaginous tissue and bony trabeculae with fibro collagenous tissue with necrosis, mature adipose cells, large number of mononuclear inflammatory cells and histiocytes.

**Note :** All biopsy specimen will be stored for 15 (fifteen) days, block and slides for 5 (five) years only from the time of receipt at the laboratory. No request, for any of the above, will be entertained after the due date.

#### **Reference**

- i) Rosai and Ackerman's Surgical Pathology.
- ii) Modern Surgical Pathology.

A handwritten signature in black ink, appearing to read 'Gulshan', written over a light blue rectangular background.

**Gulshan Yadav, MD**  
Consultant Pathologist