

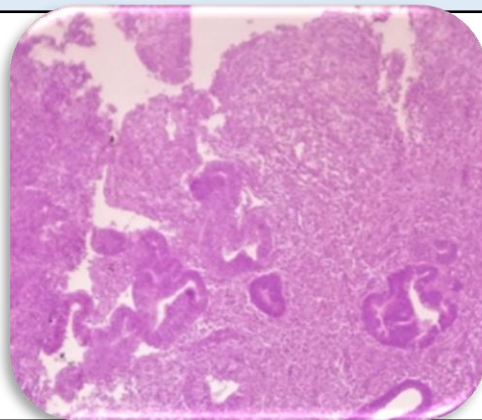
<b>Patient Name</b>	<b>Mrs. MEENAKASHI</b>	<b>Client Name</b>	Health Medicos, Rohtak	<b>Specimen Received</b>	31/07/2018
<b>Age/Sex</b>	23/F	<b>Client Code</b>	MolQ1394CM	<b>Specimen Type</b>	Tissue
<b>Patient ID</b>	011807310004	<b>Ref. Doctor</b>	Dr. SURENDER YADAV	<b>Collection Date</b>	31/07/2018
<b>Specimen ID</b>	MOLQ/B-780/18			<b>Report Date</b>	01/08/2018

## SURGICAL PATHOLOGY REPORT

### ENDOMETRIUM

#### DIAGNOSIS

**KINDLY, CO-RELATE CLINICALLY**



#### **SPECIMEN**

Endometrium.

#### **GROSS**

Received in multiple greyish white tissue pieces.

#### **Microscopy**

1. Section examined shows scanty broken endometrial glands with cuboidal lining epithelial with large number of RBCs.
2. No malignant and no granuloma seen in sample received.

**Note :** All biopsy specimen will be stored for 15 (fifteen) days, block and slides for 5 (five) years only from the time of receipt at the laboratory. No request, for any of the above, will be entertained after the due date.

#### **Reference**

- i) Rosai and Ackerman's Surgical Pathology.
- ii) Modern Surgical Pathology.

**Gulshan Yadav, MD  
Consultant Pathologist**