

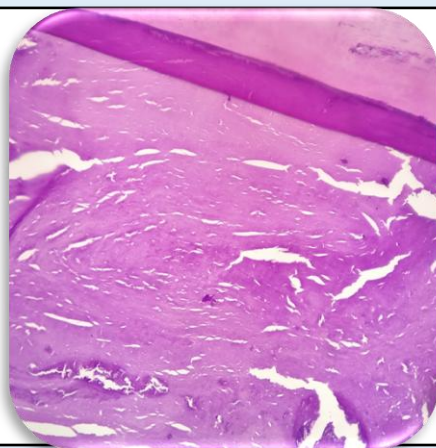
Patient Name	Mrs. NILIMA SHINHA	Client Name	Polaris Hospital, Gurgoan	Specimen Received	30/07/2018
Age/Sex	65/F	Client Code	MOLQ1098CM	Specimen Type	Tissue
Patient ID	011807300148	Ref. Docto		Collection Date	30/07/2018
Specimen ID	MOLQ/B-777-18			Report Date	31/07/2018

SURGICAL PATHOLOGY REPORT

CYST HEAD.

DIAGNOSIS

HYPERKERATOTIC LESION.



SPECIMEN

Cyst head.

GROSS

Received 1x1cm greyish white tissue piece E/A.

Microscopy

1. Section examined shows Squamous lining epithelial with hyperkeratosis.
2. No malignant and no granuloma seen.

Note : All biopsy specimen will be stored for 15 (fifteen) days, block and slides for 5 (five) years only from the time of receipt at the laboratory. No request, for any of the above, will be entertained after the due date.

Reference

- i) Rosai and Ackerman's Surgical Pathology.
- ii) Modern Surgical Pathology.

Gulshan Yadav, MD
Consultant Pathologist