

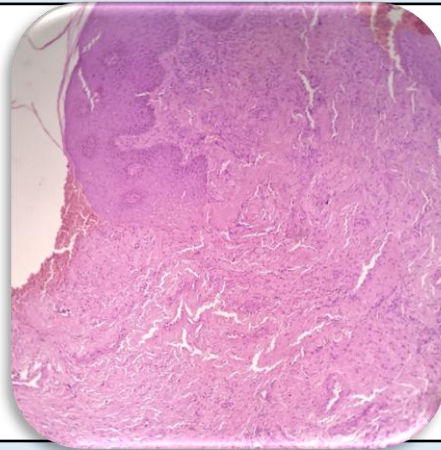
<b>Patient Name</b>	<b>Mr. NANNE KHAN</b>	<b>Client Name</b>	Unique Lab, Tauru	<b>Specimen Received</b>	28/07/2018
<b>Age/Sex</b>	51/M	<b>Client Code</b>		<b>Specimen Type</b>	Tissue
<b>Patient ID</b>	011807280245	<b>Ref. Docto</b>		<b>Collection Date</b>	28/07/2018
<b>Specimen ID</b>	MOLQ/B-771-18			<b>Report Date</b>	31/07/2018

## SURGICAL PATHOLOGY REPORT

### PILES

#### DIAGNOSIS

**HYPERPLASTIC TISSUE WITH HEMORRHOIDS.**



#### **SPECIMEN**

Piles

#### **GROSS**

Received 1.0 x 1.0 cm greyish white tissue piece.  
E/A

#### **Microscopy**

1. Section examined shows squamous epithelial lining with round vesicular nucleus.
2. Dermis shows fibrocollagenous tissue, blood vessels and inflammatory cells.

**Note :** All biopsy specimen will be stored for 15 (fifteen) days, block and slides for 5 (five) years only from the time of receipt at the laboratory. No request, for any of the above, will be entertained after the due date.

#### **Reference**

- i) Rosai and Ackerman's Surgical Pathology.
- ii) Modern Surgical Pathology.

**Gulshan Yadav, MD**  
**Consultant Pathologist**