

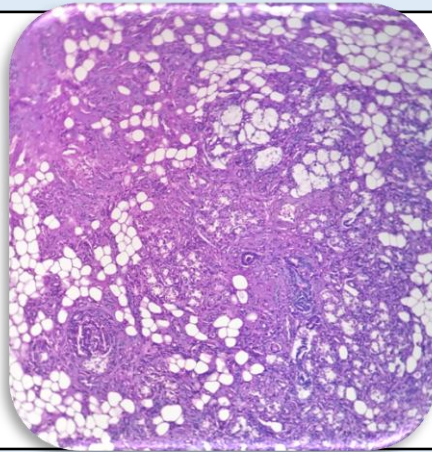
<b>Patient Name</b>	<b>Mrs. KRISHNA</b>	<b>Client Name</b>	Civil Hospital-P	<b>Specimen Received</b>	24/07/2018
<b>Age/Sex</b>	56/F	<b>Client Code</b>	MolQ1681P	<b>Specimen Type</b>	Tissue
<b>Patient ID</b>	011807240251	<b>Ref. Docto</b>	Dr. SABINA BANSAL	<b>Collection Date</b>	24/07/2018
<b>Specimen ID</b>	MOLQ/B-750-18			<b>Report Date</b>	30/07/2018

## SURGICAL PATHOLOGY REPORT

### MUCOCELE? UPPER LIP

#### DIAGNOSIS

**INFLAMMATORY CYSTIC LESION**



#### **SPECIMEN**

Mucocele? Upper Lip

#### **GROSS**

Received multiple greyish white tissue piece.

#### **Microscopy**

1. Section examined shows multiple bits of tissue minor salivary gland acini with interlobular and intralobular ducts interspersed with inflammatory infiltrate chiefly composed of neutrophils, lymphocytes and plasma cells.
2. Presence of granulation tissue response.

**Note :** All biopsy specimen will be stored for 15 (fifteen)days, block and slides for 5(five) years only from the time of receipt at the laboratory. No request ,for any of the above ,will be entertained after the due date.

#### **Reference**

- i) Rosai and Ackerman's Surgical Pathology.
- ii) Modern Surgical Pathology.

**Gulshan Yadav, MD**  
**Consultant Pathologist**