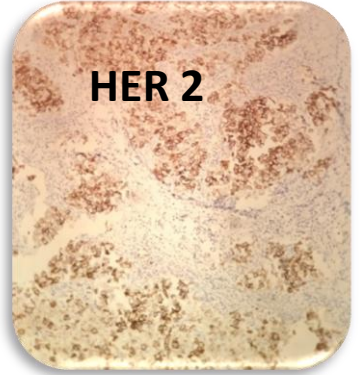
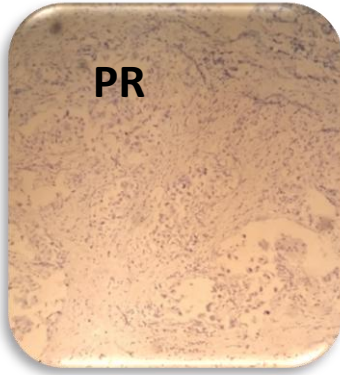
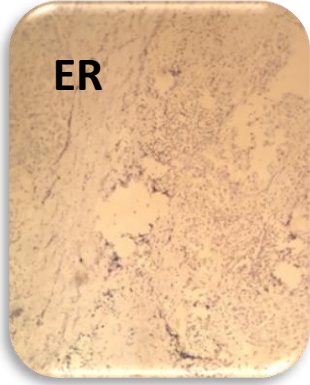
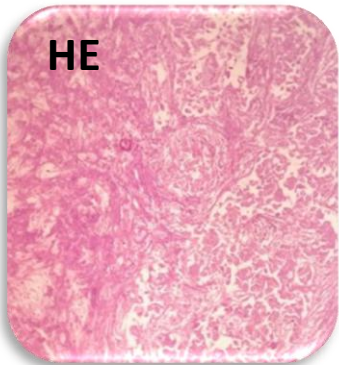


Patient Name	Mrs. SAVITRI	Client Name	Ubuntu Health Solutions	Specimen Received	18/07/2018
Age/Sex	40/F		Pvt. Ltd, Rhotak	Specimen Type	Tissue
Patient ID	011807180328	Client Code	MolQ1517CM	Collection Date	18/07/2018
Specimen ID	MOLQ/IHC-28/07/2018	Ref. Doctor	DR ANAND YADAV	Report Date	28/07/2018

SURGICAL PATHOLOGY REPORT
DUCTAL CELL CARCINOMA, STAGE II

DIAGNOSIS

Estrogen Receptor α - Negative
Progesterone Receptor- Negative
Her-2/neu-Positive



Microscopic Findings:

Estrogen Receptor α (ER)

% Cells immunoreactive – 0%
 Intensity- Not applicable
 Internal control-Positive
 Interpretation-Negative

Progesterone Receptor (PR)

% Cells immunoreactive – 0%
 Intensity- Not applicable
 Internal control-Positive
 Interpretation-Negative

Her-2/neu

% Cells immunoreactive – 30%
 Intensity-+3
 Internal control-Positive
 Interpretation-Positive

Results Estrogen Receptor α - Negative

Progesterone Receptor- Negative
 Her-2/neu-Positive

Reference

- i) Rosai and Ackerman's Surgical Pathology.
- ii) Modern Surgical Pathology.

SPECIMEN

ModifiedRadicalMastectomy(MRM)
 Right Breast.

Gulshan Yadav, MD
Consultant Pathologist