

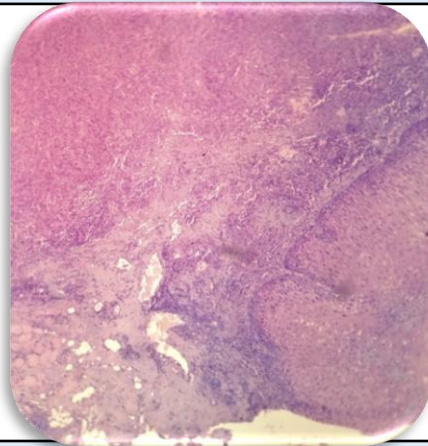
<b>Patient Name</b>	Mr. DEEVAN	<b>Client Name</b>	Lifeaid Wellness Centre,	<b>Specimen Received</b>	26/07/2018
<b>Age/Sex</b>	35/M		Gurgaon.	<b>Specimen Type</b>	Tissue
<b>Patient ID</b>	011807260010	<b>Client Code</b>	MolQ1476CM	<b>Collection Date</b>	26/07/2018
<b>Specimen ID</b>	MOLQ/B-760-18	<b>Ref. Doctor</b>		<b>Report Date</b>	28/07/2018

## SURGICAL PATHOLOGY REPORT

### CARCINOMA ? LEFT BUCCAL MUCOSA+ RETROMOLAR TRIAGONE

#### DIAGNOSIS

**ORAL SQUAMOUS CELL CARCINOMA.**



#### **SPECIMEN**

Carcinoma ? Left Buccal  
Mucosa+ Retromolar Triagone

#### **GROSS**

Received 0.5 x 0.5 cm greyish white tissue piece.

#### **Microscopy**

1. Section examined shows continuous epithelium with broad and wide rete pegs with dysplasia (anisonucleosis, basilar hyperplasia, nuclear hyperchromatism, loss of cohesion, increased mitotic activity). Presence of with tumor epithelial cells infiltrating the connective tissue stroma in form of cords and nests.
2. Stroma shows inflammatory cells , hyalinization and muscle bundles.

**Note :** All biopsy specimen will be stored for 15 (fifteen)days, block and slides for 5(five) years only from the time of receipt at the laboratory. No request ,for any of the above ,will be entertained after the due date.

#### **Reference**

- i) Rosai and Ackerman's Surgical Pathology.
- ii) Modern Surgical Pathology.

**Gulshan Yadav, MD**  
Consultant Pathologist