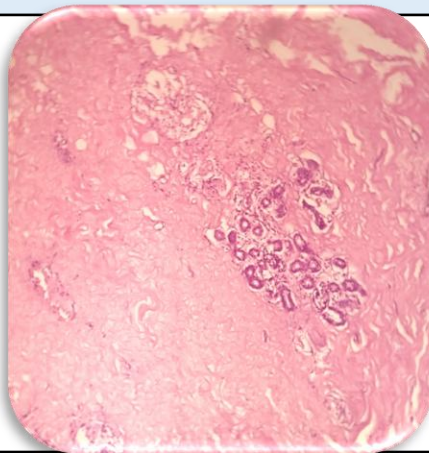


Patient Name	Miss. PRITI	Client Name	Civil Hospital-P, Gurgaon	Specimen Received	23/07/2018
Age/Sex	16/F	Client Code	MolQ1681P	Specimen Type	Tissue
Patient ID	011807230275	Ref. Doctor	DR SAURABH DESWAL	Collection Date	23/07/2018
Specimen ID	MOLQ/B-747-18			Report Date	25/07/2018

SURGICAL PATHOLOGY REPORT
FIBROADENOMA (BREAST)

DIAGNOSIS

BENIGN BREAST LESION



SPECIMEN

Fibroadenoma (Breast)

GROSS

Received two tissue piece 3.0 x 2.1cm and 3.2 x 2.3cm. greyish white tissue piece.

Microscopy

- Section examined shows large number of ducts lined by cuboidal to columnar lining epithelium with small round to oval nucleus surrounded by fibro collagenous and inflammatory cells.

Note : All biopsy specimen will be stored for 15 (fifteen)days, block and slides for 5(five) years only from the time of receipt at the laboratory. No request ,for any of the above ,will be entertained after the due date.

Reference

- Rosai and Ackerman's Surgical Pathology.
- Modern Surgical Pathology.

Gulshan Yadav, MD
Consultant Pathologist