

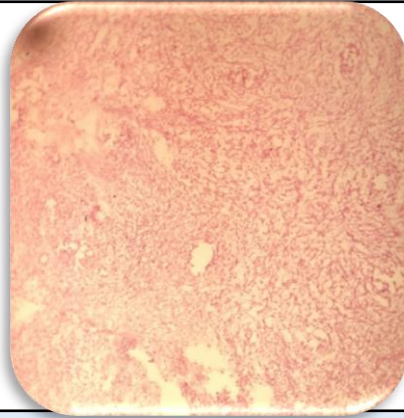
<b>Patient Name</b>	<b>Mrs. SEEMA YADAV</b>	<b>Client Name</b>	North Delhi Diagnostic,	<b>Specimen Received</b>	22/07/2018
<b>Age/Sex</b>	40/F		New Delhi	<b>Specimen Type</b>	Tissue
<b>Patient ID</b>	011807220138	<b>Client Code</b>	MolQ1219P	<b>Collection Date</b>	22/07/2018
<b>Specimen ID</b>	MOLQ/B-745/18	<b>Ref. Doctor</b>	SKY LINE HOSPITAL	<b>Report Date</b>	25/07/2018

## SURGICAL PATHOLOGY REPORT

### ENDOMETRIUM

#### DIAGNOSIS

#### PROLIFERATIVE PHASE



#### SPECIMEN

Endometrium.

#### GROSS

Received in multiple greyish white tissue pieces.

#### Microscopy

1. Section examined shows small endometrial glands having cuboidal lining epithelium with small round nucleus. Stroma shows mononuclear inflammatory cells.
2. No granuloma seen.
3. No malignant cells seen.

**Note :** All biopsy specimen will be stored for 15 (fifteen)days, block and slides for 5(five) years only from the time of receipt at the laboratory. No request ,for any of the above ,will be entertained after the due date.

#### Reference

- i) Rosai and Ackerman's Surgical Pathology.
- ii) Modern Surgical Pathology.

**Gulshan Yadav, MD**  
Consultant Pathologist