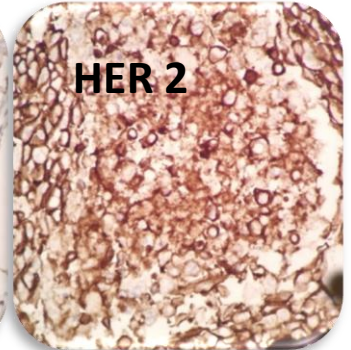
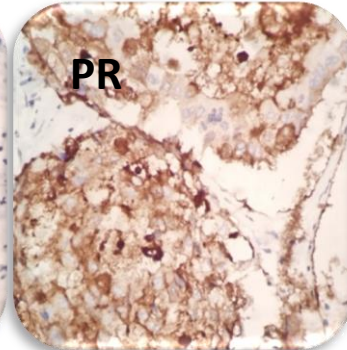
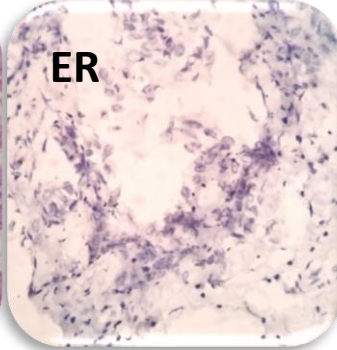
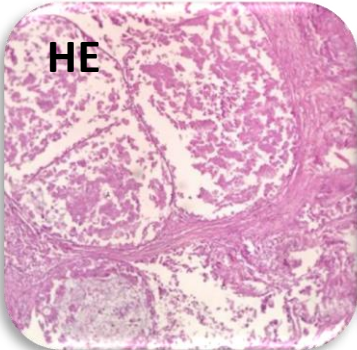


<b>Patient Name</b>	Mrs. BINDU	<b>Client Name</b>	Civil Hospital-P, Gurgaon.	<b>Specimen Received</b>	14/07/2018
<b>Age/Sex</b>	35/M	<b>Client Code</b>	MolQ1681P	<b>Specimen Type</b>	Tissue
<b>Patient ID</b>	011807020239	<b>Ref. Doctor</b>	DR SOURABH	<b>Collection Date</b>	14/07/2018
<b>Specimen ID</b>	MOLQ/IHC-27/07/2018			<b>Report Date</b>	24/07/2018

**SURGICAL PATHOLOGY REPORT**  
**DUCTAL CELL CARCINOMA, STAGE II**

**DIAGNOSIS**

**Estrogen Receptor  $\alpha$ - Negative**  
**Progesterone Receptor- Positive**  
**Her-2/neu-Positive**



**Microscopic Findings:**

**Estrogen Receptor  $\alpha$  (ER)**

% Cells immunoreactive –0%  
Intensity- Not applicable  
Internal control-Positive  
Interpretation-Negative

**Progesterone Receptor (PR)**

% Cells immunoreactive – 30%  
Intensity- +2  
Internal control-Positive  
Interpretation-Positive

**Her-2/neu**

Total Score-3+  
Interpretation-Positive

**Results** Estrogen Receptor  $\alpha$ - Negative  
Progesterone Receptor- Positive  
Her-2/neu-Positive

**Reference**

- i) Rosai and Ackerman's Surgical Pathology.
- ii) Modern Surgical Pathology.

**SPECIMEN**

ModifiedRadicalMastectomy(MRM)  
LeftBreast.

**Gulshan Yadav, MD**  
**Consultant Pathologist**