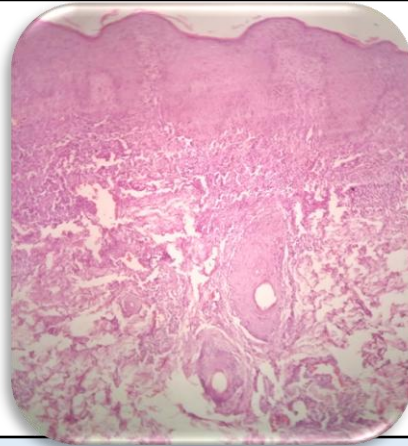


Patient Name	Mr. RAJESH	Client Name	Manvi Diagnostic ,	Specimen Received	09/07/2018
Age/Sex	37/M		Narnaul	Specimen Type	Tissue
Patient ID	011807090314	Client Code		Collection Date	09/07/2018
Specimen ID	MOLQ/B-682-18	Ref. Doctor		Report Date	24/07/2018

SURGICAL PATHOLOGY REPORT
ABDOMINAL WALL.

DIAGNOSIS

CHRONIC INFLAMMATION.



SPECIMEN

Abdominal Wall.

GROSS

Received 1.0 x 1.0 cm greyish white tissue piece.

Microscopy

1. Section examined shows squamous epithelial cells shows round to oval nucleus with mild reactive atypia.
2. Dermis shows heavy inflammatory infiltrate (Lymphocytes, plasmacytoid cells, polymorphs with few melanocytes, fibrocollagenous tissue and blood vessels).
3. No granuloma seen.

Note : All biopsy specimen will be stored for 15 (fifteen)days, block and slides for 5(five) years only from the time of receipt at the laboratory. No request ,for any of the above ,will be entertained after the due date.

Reference

- i) Rosai and Ackerman's Surgical Pathology.
- ii) Modern Surgical Pathology.

Gulshan Yadav, MD
Consultant Pathologist