

<b>Patient Name</b>	Mrs. SANJU DEVI	<b>Client Name</b>	Asian Diagnostic Centre	<b>Specimen Received</b>	14/07/2018
<b>Age/Sex</b>	28/F		New Delhi	<b>Specimen Type</b>	Tissue
<b>Patient ID</b>	011807140287	<b>Client Code</b>	MolQ1300CW	<b>Collection Date</b>	14/07/2018
<b>Specimen ID</b>	MOLQ/B-709-18	<b>Ref. Doctor</b>		<b>Report Date</b>	23/07/2018

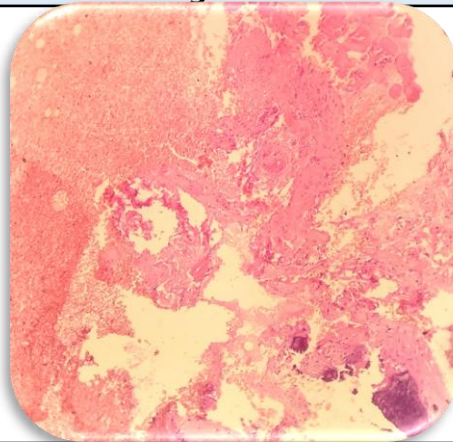
## SURGICAL PATHOLOGY REPORT

### RIGHT PROXIMAL FEMUR

#### DIAGNOSIS

**KINDLY, CO-RELATE CLINICALLY AND RADIOLOGICALLY.**

***Kindly, Provide Clinical And Radiological Detail For Proper / Confirmatory***



#### **SPECIMEN**

Right Proximal Femur.

#### **GROSS**

Received multiple greyish white tissue piece.

#### **Microscopy**

1. Section examined shows few submucosal glands with cuboidal lining epithelium, large number of mononuclear inflammatory cell.
2. Section also shows muscularis mucosa.
3. Section also shows parasitic cyst?
4. No granuloma seen.

**Note :** All biopsy specimen will be stored for 15 (fifteen)days, block and slides for 5(five) years only from the time of receipt at the laboratory. No request ,for any of the above ,will be entertained after the due date.

#### **Reference**

- i) Rosai and Ackerman's Surgical Pathology.
- ii) Modern Surgical Pathology.

**Gulshan Yadav, MD  
Consultant Pathologist**