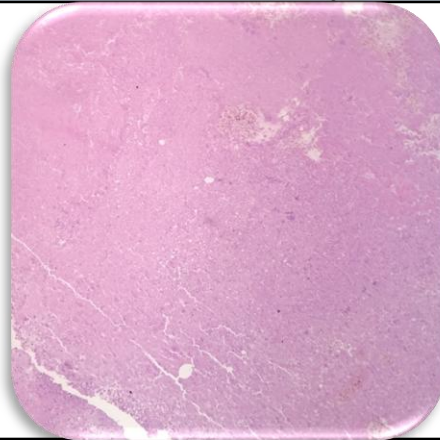


<b>Patient Name</b>	Mrs. MAYA DEVI	<b>Client Name</b>	Samvedna Hospital,	<b>Specimen Received</b>	19/07/2018
<b>Age/Sex</b>	60/F		Narnaul	<b>Specimen Type</b>	Tissue
<b>Patient ID</b>	011807190311	<b>Client Code</b>	MolQ1794CW	<b>Collection Date</b>	19/07/2018
<b>Specimen ID</b>	MOLQ/B-729-18	<b>Ref. Doctor</b>		<b>Report Date</b>	21/07/2018

**SURGICAL PATHOLOGY REPORT**  
**ULCER WITH RIGHT GROIN**

**DIAGNOSIS**

**GRANULOMATOUS REACTION.  
(TUBERCULAR PATHOLOGY TO BE RULED OUT)**



**SPECIMEN**

Ulcer with Right Groin

**GROSS**

Received multiple greyish white tissue piece.

**Microscopy**

1. Section examined shows scattered lymphocytes, centrocytes with multinucleated giant cells and necrosis.

**Note :** All biopsy specimen will be stored for 15 (fifteen)days, block and slides for 5(five) years only from the time of receipt at the laboratory. No request ,for any of the above ,will be entertained after the due date.

**Reference**

- i) Rosai and Ackerman's Surgical Pathology.
- ii) Modern Surgical Pathology.

**Gulshan Yadav, MD  
Consultant Pathologist**