

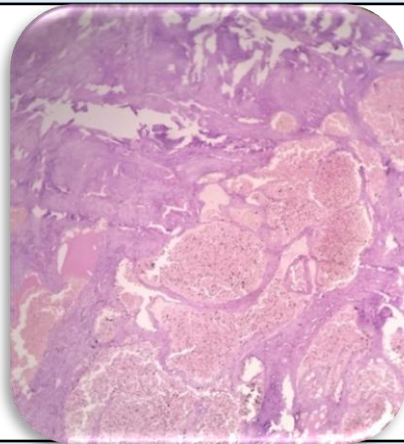
Patient Name	Mrs. RAJIYA	Client Name	Civil Hospital-P	Specimen Received	19/07/2018
Age/Sex	19/F		Gurgaon.	Specimen Type	Tissue
Patient ID	011807190209	Client Code	MOLQ1681CM	Collection Date	19/07/2018
Specimen ID	MOLQ/B-726-18	Ref. Doctor	DR PRADEEP YADAV	Report Date	21/07/2018

SURGICAL PATHOLOGY REPORT

CYST FOOT

DIAGNOSIS

BENIGN MESENCHYMAL LESION (HEMANGIOMA)



SPECIMEN

Sebaceous Cyst

GROSS

Received 5.0 X 2.9 cm greyish white tissue piece.

Microscopy

1. Section examined shows keratin flakes with bit of epithelial lining.
2. No granuloma seen.
3. No malignant cells seen.

Note : All biopsy specimen will be stored for 15 (fifteen) days, block and slides for 5 (five) years only from the time of receipt at the laboratory. No request, for any of the above, will be entertained after the due date.

Reference

- i) Rosai and Ackerman's Surgical Pathology.
- ii) Modern Surgical Pathology.

Gulshan Yadav, MD
Consultant Pathologist