

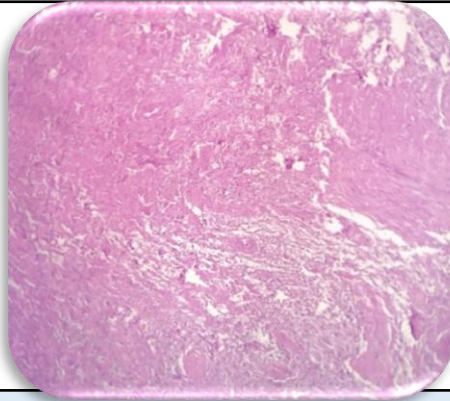
<b>Patient Name</b>	Mrs. SANTOSH	<b>Client Name</b>	Cygnus SuperSpeciality	<b>Specimen Received</b>	14/07/2018
<b>Age/Sex</b>	51/F		Hospital, Rewari	<b>Specimen Type</b>	Tissue
<b>Patient ID</b>	011807140358	<b>Client Code</b>	MolQ1687CM	<b>Collection Date</b>	14/07/2018
<b>Specimen ID</b>	MOLQ/B-711-18	<b>Ref. Doctor</b>		<b>Report Date</b>	18/07/2018

## SURGICAL PATHOLOGY REPORT

### GALL BLADDER.

#### DIAGNOSIS

**CHOLECYSTITIS AND CHOLELITHIASIS.**



#### SPECIMEN

Gall Bladder.

#### GROSS

Received 6.0 x 3.2 cms long gall bladder already cut open with tiny stone.


#### Microscopy

1. Section examined shows ulcerative mucosa and Rokitansky-Aschoff sinuses with fibrocollagenous tissue.

**Note :** All biopsy specimen will be stored for 15 (fifteen) days, block and slides for 5 (five) years only from the time of receipt at the laboratory. No request, for any of the above, will be entertained after the due date.

#### Reference

- i) Rosai and Ackerman's Surgical Pathology.
- ii) Modern Surgical Pathology.



**Gulshan Yadav, MD**  
Consultant Pathologist