

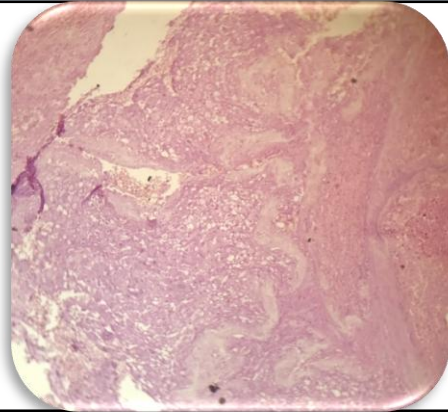
Patient Name	Mrs. NARESH	Client Name	Path Star Diagnostic,	Specimen Received	12/07/2018
Age/Sex	38/F		New Delhi	Specimen Type	Tissue
Patient ID	011807120324	Client Code	MOLQ1098CM	Collection Date	12/07/2018
Specimen ID	MOLQ/B-701/18	Ref. Doctor		Report Date	16/07/2018

SURGICAL PATHOLOGY REPORT

ENDOMETRIUM.

DIAGNOSIS

HYPERPROGESTRONIC EFFECT.



SPECIMEN

Endometrium.

GROSS

Received multiple greyish white tissue piece

Microscopy

1. Section examined shows small and tortuous endometrial glands with decidual cells, fibrin material and RBCs.
2. Stroma shows mononuclear inflammatory cells.
3. No granuloma seen.
4. No malignant cells seen.

Note : All biopsy specimen will be stored for 15 (fifteen)days, block and slides for 5(five) years only from the time of receipt at the laboratory. No request ,for any of the above ,will be entertained after the due date.

Reference

- i) Rosai and Ackerman's Surgical Pathology.
- ii) Modern Surgical Pathology.

Gulshan Yadav, MD
Consultant Pathologist