

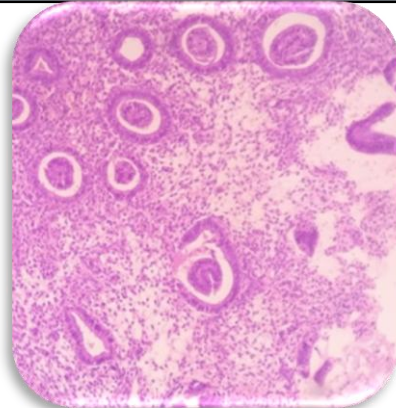
Patient Name	Mrs. ANJU	Client Name	Health Medicos, Rohtak	Specimen Received	11/07/2018
Age/Sex	20/F	Client Code	MolQ1394CM	Specimen Type	Tissue
Patient ID	011807110309	Ref. Doctor		Collection Date	11/07/2018
Specimen ID	MOLQ/B-691/18			Report Date	16/07/2018

SURGICAL PATHOLOGY REPORT

ENDOMETRIUM.

DIAGNOSIS

DISORDERED PROLIFERATIVE PHASE WITH DECIDUAL CELLS.



SPECIMEN

Endometrium.

GROSS

Received multiple greyish white tissue piece

Microscopy

1. Section examined shows small and tortuous endometrial glands having columnar lining epithelium with vacuoles.
2. Stroma shows mononuclear inflammatory cells and decidual cells.
3. No malignant and no granuloma seen.

Note : All biopsy specimen will be stored for 15 (fifteen)days, block and slides for 5(five) years only from the time of receipt at the laboratory. No request ,for any of the above ,will be entertained after the due date.

Reference

- i) Rosai and Ackerman's Surgical Pathology.
- ii) Modern Surgical Pathology.

Gulshan Yadav, MD
Consultant Pathologist