

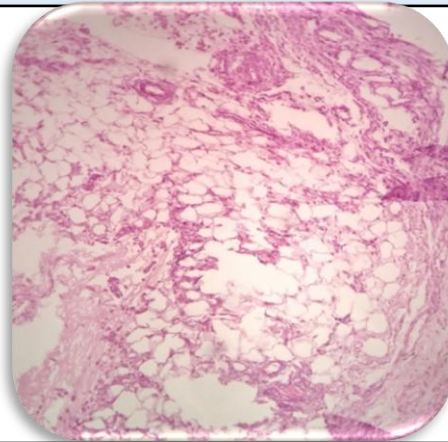
<b>Patient Name</b>	Mrs. POSHA	<b>Client Name</b>	A-One Collection Centre,	<b>Specimen Received</b>	07/07/2018
<b>Age/Sex</b>	38/F		Jammu & Kashmir	<b>Specimen Type</b>	Tissue
<b>Patient ID</b>	041807070036	<b>Client Code</b>	MolQ1671CM	<b>Collection Date</b>	07/07/2018
<b>Specimen ID</b>	MOLQ/B-672-18	<b>Ref. Doctor</b>	Health Cresent	<b>Report Date</b>	12/07/2018

## SURGICAL PATHOLOGY REPORT

### Right Ovarian Cyst.

#### DIAGNOSIS

**HAEMORRHAGIC CYST.**



#### SPECIMEN

Right Ovarian Cyst.

#### GROSS

Received 10.0 x 4.2 cms uterus with bilateral adnexa, ovary shows 3.0 x 2.0 cms, 4.0 x 2.5 cm.

#### Microscopy

Section examined shows

1. Section examined shows ovarian tissue, mature adipose tissue, fibro collagenous tissue, blood vessels, inflammatory cells with large number of RBCs.
2. No endometrial glands or trophoblastic cells seen.
3. No malignant cells seen.

**Note :** All biopsy specimen will be stored for 15 (fifteen)days, block and slides for 5(five) years only from the time of receipt at the laboratory. No request ,for any of the above ,will be entertained after the due date.

#### Reference

- i) Rosai and Ackerman's Surgical Pathology.
- ii) Modern Surgical Pathology.

**Gulshan Yadav, MD**  
Consultant Pathologist