

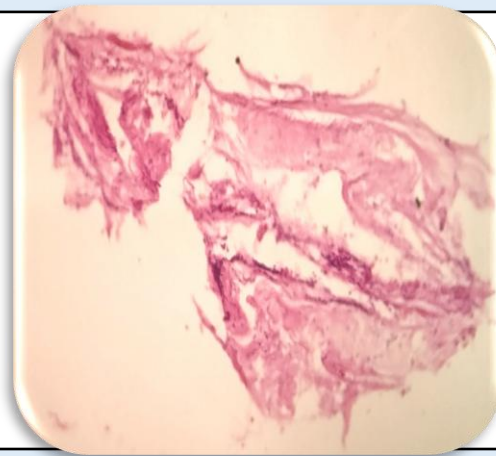
Patient Name	Mrs. NARSO DEVI	Client Name	Accurate Path (C), Agra	Specimen Received	10/07/2018
Age/Sex	40/F	Client Code	MolQ1671CM	Specimen Type	Tissue
Patient ID	011807100006	Ref. Doctor		Collection Date	10/07/2018
Specimen ID	MOLQ/B-684-18			Report Date	14/07/2018

SURGICAL PATHOLOGY REPORT

OVARIAN CYST.

DIAGNOSIS

CYSTADENOMA.



SPECIMEN

Ovarian Cyst.

GROSS

Received 6.0 x 4.0 cm multiloculated cyst. Cut section shows clear fluid.

Microscopy

1. Section examined shows lining epithelium with round to oval nucleus and fibro collagenous tissue (stromal cells) which is unremarkable.

Dermis shows fibrocollagenous tissue, calcified areas and few mononuclear cell infiltrate.

2. No granuloma seen.

Note : All biopsy specimen will be stored for 15 (fifteen) days, block and slides for 5 (five) years only from the time of receipt at the laboratory. No request, for any of the above, will be entertained after the due date.

Reference

- i) Rosai and Ackerman's Surgical Pathology.
- ii) Modern Surgical Pathology.

Gulshan Yadav, MD
Consultant Pathologist